

VIDEOS IN CLINICAL MEDICINE

Paracentesis

Todd W. Thomsen, M.D., Robert W. Shaffer, M.D., Benjamin White, M.D.,
and Gary S. Setnik, M.D.

INDICATIONS

Abdominal paracentesis should be performed in all adult patients presenting with new-onset ascites of uncertain causation. Evaluation of the ascitic fluid will determine whether the ascites is due to portal hypertension or to another process, such as cancer, infection, or pancreatitis.^{1,2}

Diagnostic paracentesis should also be performed in patients with preexisting ascites when spontaneous bacterial peritonitis (SBP) is suspected. SBP is common in patients with ascites and may be life-threatening; clinical indicators include fever, abdominal pain, worsening encephalopathy, worsening renal function, leukocytosis, acidosis, gastrointestinal bleeding, sepsis, and shock.² In addition, some experts recommend that all patients with cirrhosis and ascites requiring hospitalization undergo a surveillance paracentesis, since occult SBP is not uncommon in these patients.¹

Large-volume paracentesis may be performed to alleviate discomfort or respiratory compromise in patients with tense ascites who are in hemodynamically stable condition.³ Serial large-volume paracenteses may be required in patients with refractory ascites or ascites that does not respond to diuretics.

CONTRAINDICATIONS

Many patients undergoing paracentesis will have baseline coagulopathy or thrombocytopenia as a result of underlying hepatic disease. However, the incidence of clinically significant bleeding complications in such patients is low (a recent retrospective study of more than 4500 paracenteses reported severe hemorrhage in <0.2% of procedures⁴), and the routine use of fresh-frozen plasma or platelet concentrates is not recommended.^{1,3,5} The risk of bleeding complications may be somewhat higher in patients with markedly increased serum creatinine levels, and extended post-procedure observation should be considered in these patients.⁵ Paracentesis should be avoided in patients with disseminated intravascular coagulation.¹

The procedure should be performed with caution in pregnant patients or in patients who have organomegaly, bowel obstruction, intraabdominal adhesions, or a distended urinary bladder. The use of ultrasonographic guidance in these situations may reduce the risk of iatrogenic injury. Nasogastric intubation should be performed before paracentesis in patients with bowel obstructions, and patients with urinary retention should first undergo urethral catheterization.⁶

The paracentesis catheter should not pass through sites of cutaneous infection, visibly engorged cutaneous vessels, surgical scars, or abdominal-wall hematomas.⁶

EQUIPMENT

Various prepackaged paracentesis kits (e.g., Safe-T-Centesis Catheter Drainage Tray, Cardinal Health; Large Volume Abdominal Paracentesis Kit, Arrow International) are commercially available. You should become familiar with specific devices available at your institution. Traditional large-bore intravenous catheters can be used to per-

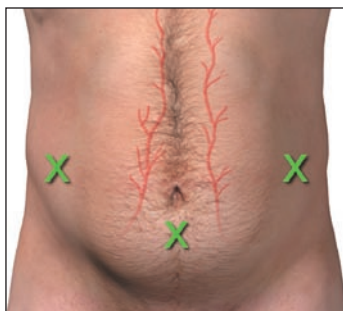From the Department of Emergency Medicine, Mount Auburn Hospital, Cambridge, MA (T.W.T., R.W.S., G.S.S.); the Department of Emergency Medicine, Brigham and Women's Hospital, Boston (B.W.); and the Division of Emergency Medicine, Harvard Medical School, Boston (T.W.T., R.W.S., B.W., G.S.S.). Address reprint requests to Dr. Thomsen at the Department of Emergency Medicine, Mount Auburn Hospital, 330 Mount Auburn St., Cambridge, MA 02238, or at tthomsen@mah.harvard.edu.

N Engl J Med 2006;355:e21.
Copyright © 2006 Massachusetts Medical Society.

form paracentesis; however, they are not specifically designed for the procedure, and their use is discouraged. The use of intravenous catheters results in slower flow rates and frequently requires multiple punctures, which may increase the risk of complications.^{7,8} Some devices made specifically for paracentesis are equipped with a blunt retractable obturator to reduce the incidence of organ injury and multiple drainage holes at the distal end of the catheter, to prevent the interruption of ascitic fluid flow. Regardless of the equipment chosen, the method described below can be used with any over-the-needle catheter device.

PREPARATION

Explain the procedure to the patient, and obtain written informed consent. You should also discuss the risks of bleeding, infection, injury to intraabdominal organs, and post-procedure hypotension. Enlist an assistant to help fill the specimen tubes, culture bottles, and evacuated containers.



Needle-entry sites

Place the patient supine in the bed with his or her head slightly elevated. Recommended needle-insertion sites include a point 2 cm below the umbilicus in the midline or in the right or left lower quadrant, 2 to 4 cm medial and cephalad to the anterior superior iliac spine.⁶ The advantage of the midline approach is that the linea alba in this region is devoid of blood vessels.⁶ In obese patients, however, the left lateral approach may be preferable, because the abdominal wall is thinner and the depth of ascitic fluid is deeper in this region than in the midline.¹ If you choose the lateral approach, you must insert the needle lateral to the rectus sheath to avoid puncturing the inferior epigastric artery.⁶ The presence of ascites at the chosen insertion site is suggested by a sense of shifting “dullness.” Bedside ultrasonography, if available, should be used to find an appropriate location that contains ascitic fluid but is devoid of loops of bowel or solid organs, especially in patients who are overweight or who have multiple surgical scars. Mark the chosen entry site with a skin-marking pen.

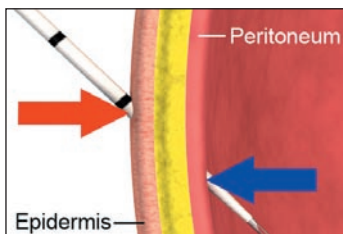
Paracentesis should be performed in a sterile manner. Sterile gloves and a face shield are required; a sterile gown may be worn but is not necessary. Cleanse the patient’s skin with antiseptic solution, and then apply a sterile drape.

With a 22- or 25-gauge, 1.5-in. (or longer) needle, place a wheal of local anesthetic (e.g., 1 ml of 1 or 2% lidocaine) in the epidermis at the entry site. Anesthetize the deeper tissues by slowly advancing the needle along the anticipated trajectory of the paracentesis needle, alternatively injecting anesthetic and pulling back on the plunger (to ensure the needle has not penetrated a vascular structure). You may feel a sudden loss of resistance once the needle enters the peritoneal cavity. Stop advancing the needle as soon as peritoneal fluid begins to fill the syringe, and inject additional anesthetic (3 to 5 ml) to anesthetize the highly sensitive parietal peritoneum. A total of 5 to 10 ml of lidocaine is generally used.

PARACENTESIS

Make a small puncture at the site of insertion with either a large-bore (18-gauge) needle or a scalpel with a number 11 blade to facilitate advancement of the paracentesis catheter through the epidermis. Attach a 5- to 10-ml syringe to the catheter assembly in preparation for peritoneal puncture.

There are two acceptable techniques for advancing the catheter through the skin, subcutaneous tissues, and parietal peritoneum.⁹ In the angular insertion technique, the needle is held at a 45-degree angle as it pierces the epidermis, and it continues on this trajectory through the subcutaneous tissues and into the peritoneal cavity. In the Z-tract technique, the cutaneous tissues are pulled 2 cm caudad before the

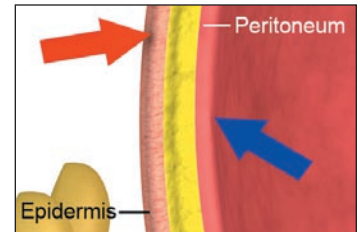
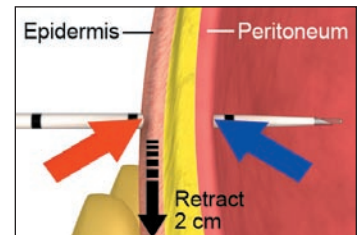


The angular insertion technique

needle is inserted and advanced. When the needle is withdrawn, the cutaneous entry site will retract to its original position. These methods prevent direct overlap of the cutaneous insertion site and the peritoneal insertion site, theoretically minimizing the risk of an ascitic fluid leak after the procedure.

Hold the syringe with your dominant hand and the shaft of the needle with your nondominant hand. Resting your nondominant hand on the patient's skin will allow you to gently direct the needle through the subcutaneous tissues. Advance the needle in small (2 to 3 mm) increments, intermittently pulling back on the plunger as you advance. Again, you may feel a sudden loss of resistance as the needle enters the peritoneal cavity. Once this occurs, or when ascitic fluid fills the syringe, immediately stop advancing the needle, carefully guide the catheter over the needle, and then withdraw the needle.

If a diagnostic sample is needed, attach a large syringe to the catheter and withdraw 30 to 60 ml of fluid. If large-volume paracentesis is required, you should attach high-pressure connection tubing to the catheter hub and then to a large evacuated container. Additional containers may be filled as necessary. Once the desired quantity of fluid has been removed, quickly remove the catheter and apply a sterile occlusive dressing.



The Z-tract technique

ANALYSIS OF PERITONEAL FLUID

Aspirated fluid should immediately be placed in appropriate specimen tubes and analyzed without delay. A tube without additives should be submitted for the measurement of albumin in the ascitic fluid. An EDTA-treated tube should be sent for a cell count and differential count. Aerobic- and anaerobic-culture bottles should be inoculated at the bedside. Additional testing may be required depending on the clinical circumstances (Table 1).^{1,6}

Serum–Ascites Albumin Gradient

The serum–ascites albumin gradient is calculated by subtracting the albumin level in ascitic fluid from the serum albumin level (obtained concurrently). Values of 1.1 g

Table 1. Additional Analyses of Ascitic Fluid.*

Test and Ascitic-Fluid Container	Comments
Tube without additives	
Total protein	Values ≥ 1 g/dl suggest secondary peritonitis instead of SBP
Lactate dehydrogenase	Values greater than the upper limit of normal for serum suggest secondary peritonitis instead of SBP
Glucose	Values < 50 mg/dl suggest secondary peritonitis instead of SBP
Carcinoembryonic antigen	Values > 5 ng/ml suggest hollow viscus perforation
Alkaline phosphatase	Values > 240 U/liter suggest hollow viscus perforation
Amylase	Values markedly elevated (often > 2000 U/liter or five times serum levels) in patients with pancreatic ascites or hollow viscus perforation
Triglyceride	Values > 200 mg/dl suggest chylous ascites
Syringe or evacuated container	
Cytology	Sensitivity increased if three samples submitted and promptly evaluated
Mycobacterial culture	Sensitivity only 50%

* Data are from Runyon.^{1,10} SBP denotes spontaneous bacterial peritonitis.

Table 2. Differential Diagnosis of Ascites According to the Serum–Ascites Albumin Gradient.*

Gradient ≥ 1.1 g/dl (portal hypertension)	Gradient < 1.1 g/dl
Cirrhosis	Peritoneal carcinomatosis
Alcoholic hepatitis	Tuberculous peritonitis
Cardiac ascites	Pancreatic ascites
Portal-vein thrombosis	Biliary ascites
Budd–Chiari syndrome	Nephrotic syndrome
Liver metastases	Serositis

* Data are from Marx.⁶

per deciliter or greater indicate portal hypertension as the cause of the ascites with an accuracy of 97%. Values of less than 1.1 g per deciliter are indicative of other causes (Table 2).²

Spontaneous Bacterial Peritonitis

The diagnosis of SBP is suggested by a polymorphonuclear (PMN) cell count in excess of 250 cells per cubic millimeter in the absence of evidence of an alternative source of infection (secondary peritonitis), such as viscus perforation or intraabdominal abscess. In the event of a traumatic tap and a grossly bloody aspirate, the total PMN cell count can be estimated by subtracting 1 PMN cell for every 250 red cells.¹⁰ Determination of total protein, lactate dehydrogenase, and glucose levels in ascitic fluid may aid in the differentiation between SBP and secondary peritonitis (Table 1). Culture is used to confirm the diagnosis of SBP.¹

Patients who receive a diagnosis of SBP should be treated with both antibiotics (typically a third-generation cephalosporin) and intravenous albumin.¹¹

COMPLICATIONS

Circulatory dysfunction may occur after large-volume paracentesis and is associated with hypotension, hyponatremia, and increased plasma catecholamine and renin levels. Severe cases may lead to the hepatorenal syndrome and even death.² Although the use of albumin as a plasma expander remains controversial (owing to its high cost and lack of evidence of survival benefit), many experts recommend its use in patients who have had more than 5 liters of ascitic fluid removed.^{1–3} The dose of albumin is 6 to 8 g per liter of fluid removed, administered intravenously after the completion of the procedure.¹

Other complications of paracentesis are rare and include persistent leakage of ascitic fluid, localized infection, and abdominal-wall hematoma. More serious complications, also rare, include hemorrhage (with an estimated incidence of less than 0.2%⁴), injury to intraabdominal organs, and puncture of the inferior epigastric artery.

REFERENCES

- Runyon BA. Management of adult patients with ascites due to cirrhosis. *Hepatology* 2004;39:841-56.
 - Sandhu BS, Sanyal AJ. Management of ascites in cirrhosis. *Clin Liver Dis* 2005; 9:715-32.
 - Ginès P, Cárdenas A, Arroyo V, Rodés J. Management of cirrhosis and ascites. *N Engl J Med* 2004;350:1646-54.
 - Pache I, Bilodeau M. Severe haemorrhage following abdominal paracentesis for ascites in patients with liver disease. *Aliment Pharmacol Ther* 2005;21:525-9.
 - McVay PA, Toy PTCY. Lack of increased bleeding after paracentesis and thoracentesis in patients with mild coagulation abnormalities. *Transfusion* 1991;31: 164-71.
 - Marx JA. Peritoneal procedures. In: Roberts JR, Hedges J, eds. *Clinical procedures in emergency medicine*. 4th ed. Philadelphia: Saunders, 2004:851-6.
 - Shaheen NJ, Grimm IS. Comparison of the Caldwell needle/cannula with Angiocath needle in large volume paracentesis. *Am J Gastroenterol* 1996;91:1731-3.
 - Schlottmann K, Gelbmann C, Grune S, Lock G, Scholmerich J. A new paracentesis needle for ascites and pleural effusion compared with the venous indwelling catheter: a prospective, randomized study. *Med Klin (Munich)* 2001;96:321-4. (In German.)
 - Promes SB. Paracentesis. In: Reichman EF, Simon RR. *Emergency medicine procedures*. New York: McGraw-Hill, 2004: 467-77.
 - Runyon B. Ascites and spontaneous bacterial peritonitis. In: Feldman M, Friedman LS, Sleisenger MH, eds. *Sleisenger & Fordtran's gastrointestinal and liver disease*. 7th ed. Philadelphia: Saunders, 2002: 1517-42.
 - Sort P, Navasa M, Arroyo V, et al. Effect of intravenous albumin on renal impairment and mortality in patients with cirrhosis and spontaneous bacterial peritonitis. *N Engl J Med* 1999;341:403-9.
- Copyright © 2006 Massachusetts Medical Society.

CORRECTION

Paracentesis

Paracentesis . In Table 1 of the PDF summary, the entry for lactate dehydrogenase should have read "Values greater than the upper limit of normal for serum suggest secondary peritonitis instead of SBP," rather than "Values less than the upper limit." We regret the error. The table has been corrected on the *Journal's* Web site at www.nejm.org.