

Does This Patient With a Pericardial Effusion Have Cardiac Tamponade?

Christopher L. Roy, MD

Melissa A. Minor, MD

M. Alan Brookhart, PhD

Nitesh K. Choudhry, MD, PhD

CLINICAL SCENARIOS

Case 1

A 55-year-old woman with chronic obstructive pulmonary disease presents to your office with 2 weeks of progressive dyspnea. She had breast cancer diagnosed and treated more than 10 years ago and has had no evidence of recurrence. She was seen in the emergency department 1 week ago, where her evaluation included an echocardiogram that demonstrated a moderate-sized (15 mm in maximum width), circumferential pericardial effusion without echocardiographic evidence of cardiac tamponade. During your examination, you note tachycardia and faint heart sounds. A pulsus paradoxus is 6 mm Hg with a blood pressure of 100/60 mm Hg, the jugular venous pressure is not elevated, and auscultation of her lungs reveals diminished breath sounds. You obtain a chest radiograph that is unchanged from previous films and that shows hyperinflated, clear lung fields and no enlargement of the cardiac silhouette. You suspect that the patient's symptoms are attributable to her lung disease, but should you evaluate further for tamponade?

Case 2

A previously healthy 34-year-old man presents to the emergency department with dyspnea for the past 3 days.

See also Patient Page.

CME available online at
www.jama.com

Context Cardiac tamponade is a state of hemodynamic compromise resulting from cardiac compression by fluid trapped in the pericardial space. The clinical examination may assist in the decision to perform pericardiocentesis in patients with cardiac tamponade diagnosed by echocardiography.

Objective To systematically review the accuracy of the history, physical examination, and basic diagnostic tests for the diagnosis of cardiac tamponade.

Data Sources MEDLINE search of English-language articles published between 1966 and 2006, reference lists of these articles, and reference lists of relevant textbooks.

Study Selection We included articles that compared aspects of the clinical examination to a reference standard for the diagnosis of cardiac tamponade. We excluded studies with fewer than 15 patients. Of 787 studies identified by our search strategy, 8 were included in our final analysis.

Data Extraction Two authors independently reviewed articles for study results and quality. A third reviewer resolved disagreements.

Data Synthesis All studies evaluated patients with known tamponade or those referred for pericardiocentesis with known effusion. Five features occur in the majority of patients with tamponade: dyspnea (sensitivity range, 87%-89%), tachycardia (pooled sensitivity, 77%; 95% confidence interval [CI], 69%-85%), pulsus paradoxus (pooled sensitivity, 82%; 95% CI, 72%-92%), elevated jugular venous pressure (pooled sensitivity, 76%; 95% CI, 62%-90%), and cardiomegaly on chest radiograph (pooled sensitivity, 89%; 95% CI, 73%-100%). Based on 1 study, the presence of pulsus paradoxus greater than 10 mm Hg in a patient with a pericardial effusion increases the likelihood of tamponade (likelihood ratio, 3.3; 95% CI, 1.8-6.3), while a pulsus paradoxus of 10 mm Hg or less greatly lowers the likelihood (likelihood ratio, 0.03; 95% CI, 0.01-0.24).

Conclusions Among patients with cardiac tamponade, a minority will not have dyspnea, tachycardia, elevated jugular venous pressure, or cardiomegaly on chest radiograph. A pulsus paradoxus greater than 10 mm Hg among patients with a pericardial effusion helps distinguish those with cardiac tamponade from those without. Diagnostic certainty of the presence of tamponade requires additional testing.

JAMA. 2007;297:1810-1818

www.jama.com

He is found to have a pulsus paradoxus of 18 mm Hg with a blood pressure of 130/70 mm Hg and a heart rate of 90/min. The remainder of the physical examination is unremarkable. The chest radiograph shows an enlarged cardiac silhouette. You order an echocardiogram that shows a moderate-sized, circumferential pericardial effusion with a left ventricular ejection fraction of 65%. The study is limited by body habitus and rapid respirations, and the right

Author Affiliations: Divisions of General Medicine and Primary Care (Dr Roy) and Pharmacoepidemiology and Pharmacoeconomics (Drs Brookhart and Choudhry), Brigham and Women's Hospital, Harvard Medical School, Boston, Mass; Hospitalist Service, Brigham and Women's Hospital, Boston (Drs Roy and Choudhry); and Harvard Vanguard Medical Associates, Boston (Dr Minor).

Corresponding Author: Christopher L. Roy, MD, Division of General Medicine and Primary Care, Hospitalist Service, Brigham and Women's Hospital, 75 Francis St, Boston, MA 02115 (croy@partners.org).

The Rational Clinical Examination Section Editors: David L. Simel, MD, MHS, Durham Veterans Affairs Medical Center and Duke University Medical Center, Durham, NC; Drummond Rennie, MD, Deputy Editor, *JAMA*.

atrium and right ventricle are poorly visualized. Do the physical examination findings alter your assessment of this patient's pericardial effusion?

WHY IS THE CLINICAL EXAMINATION FOR CARDIAC TAMPONADE IMPORTANT?

Cardiac tamponade occurs when fluid trapped in the pericardial space compresses the heart and compromises cardiac output. The consequences of cardiac tamponade range from barely detectable effects to overt hemodynamic collapse.¹⁻³ When a pericardial effusion becomes large enough or accumulates rapidly enough to cause hemodynamic consequences, readily observed symptoms and signs herald impending circulatory collapse that necessitates urgent therapeutic intervention.

The invasive reference standard for the diagnosis of cardiac tamponade requires simultaneous measurement of intrapericardial and intracardiac pressures. The intrapericardial, right atrial, pulmonary artery diastolic, and pulmonary capillary wedge pressures are all elevated and equalized in cardiac tamponade (FIGURE 1). In the absence of other pathology (eg, effusive-constrictive disease), pericardiocentesis will normalize pressures and improve the cardiac output, confirming the diagnosis.⁴

Echocardiography is the diagnostic test used most frequently to evaluate cardiac tamponade when it is clinically suspected (FIGURE 2). While echocardiography is the noninvasive reference standard for the diagnosis of pericardial effusion,⁵ the mere presence of an effusion does not define cardiac tamponade. Rather, several echocardiographic findings, including right atrial systolic collapse, right ventricular diastolic collapse, inferior vena caval plethora, and exaggeration of respirophasic changes in flow velocities across the tricuspid and mitral valves, are indicative of tamponade physiology and make the diagnosis with near certainty when the pretest probability is high. Because cardiac tamponade occurs on a continuum of hemodynamic effects, the findings on echocardiogram may be

too sensitive and overdiagnose cardiac tamponade in patients with only subtle evidence of hemodynamic compromise.^{4,6,7} Nonetheless, because echocardiography is a noninvasive modality that is highly accurate, it is an essential component of the evaluation.⁸⁻¹¹

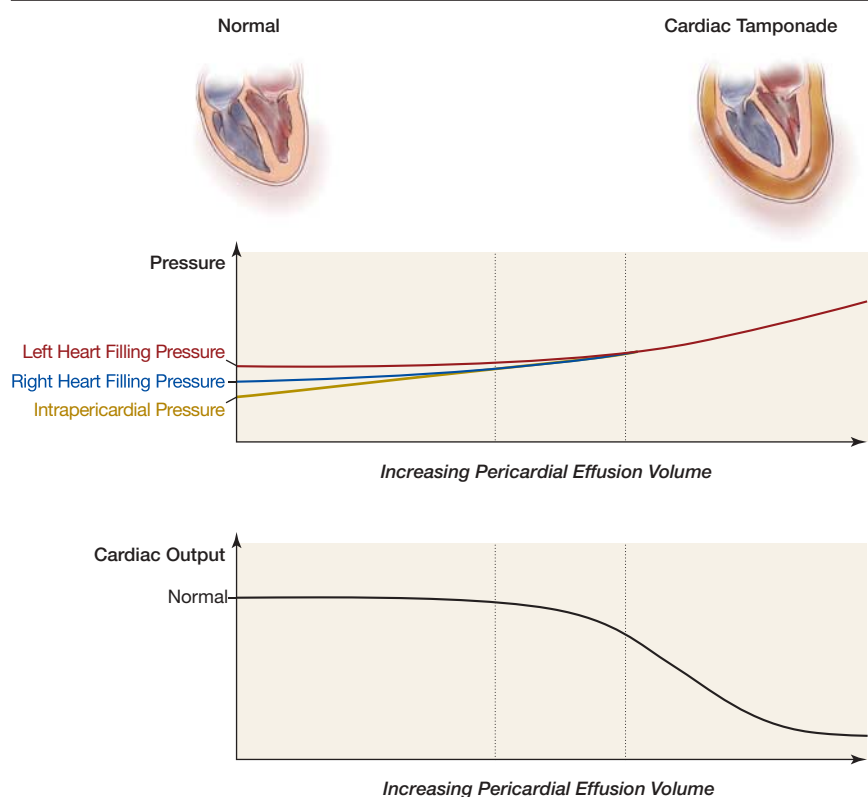
There are several scenarios in which the clinical examination for cardiac tamponade could be useful. If the clinical examination could rule out tamponade with a high degree of certainty, it could preclude the need for echocardiography in some patients and allow the clinician to pursue other potential diagnoses. On the other hand, the clinician is sometimes faced with echocardiographic findings suggestive of cardiac tamponade, and clinical correlation is necessary to guide the decision for urgent pericardiocentesis.^{6,12}

The Pathophysiology of Cardiac Tamponade

The pericardial sac consists of 2 layers: an outermost parietal pericardium and the inner visceral pericardium (epicardium) that reflects directly over the surface of the heart. Normally, no more than 15 to 30 mL of fluid exists between the 2 layers, held at pressures approximating the pleural pressure or approximately 5 mm Hg lower than central venous pressure.^{13,14}

When pericardial fluid accumulates slowly, parietal pericardium compliance increases. Increasing amounts of fluid causes intrapericardial pressure to increase, while the central venous pressure responds by increasing to maintain a gradient that allows cardiac filling. When pericardial compliance can increase no more, the intrapericardial

Figure 1. Relationship Between Intracardiac Filling Pressures and Intrapericardial Pressure and Cardiac Output in Cardiac Tamponade



As pericardial fluid volume increases to the limit of pericardial compliance, intrapericardial pressure rises. Cardiac output begins to fall as intrapericardial pressure equalizes with central venous, right atrial, and right ventricular end-diastolic pressures (right heart filling pressures), then rapidly falls as it equalizes with left atrial and left ventricular end-diastolic pressures (left heart filling pressures).

pressure first equalizes with the right ventricular diastolic pressure and then with the left (Figure 1). At this threshold, the cardiac output drops and circulation is maintained only through an increase in heart rate, contractility, and peripheral arteriolar vasoconstriction.¹⁴⁻¹⁶ Because of pericardial compliance, large amounts of fluid may accumulate before overt hemodynamic effects occur. Rapid (ie, over minutes to hours) fluid accumulation may exceed the ability of the pericardium to stretch; if so, intrapericardial pressure increases rapidly and cardiac filling is impaired, with an often dramatic drop in cardiac output.

Causes of Cardiac Tamponade

The etiology of cardiac tamponade in patients admitted to medical services mirrors the various conditions that cause pericardial effusions. The absence of population-based incidence estimates of tamponade and the paucity of data about how often pericardial effusion leads to tamponade prevents establishment of pretest probability estimates. We do know that cardiac tamponade occurs so

infrequently that the diagnosis should not be considered unless the setting is appropriate. As a result of different patient populations, practice settings, and the intensity of evaluation undertaken, the reported incidences of various etiologies of pericardial effusions vary.¹⁷⁻¹⁹ In the largest reported series, Sagristà-Sauleda et al¹⁸ reviewed the medical records of 322 Spanish patients with moderate or large effusions. The most common diagnoses were acute idiopathic pericarditis (20%), iatrogenic effusion (16%), malignancy (13%), chronic idiopathic effusion (9%), acute myocardial infarction (8%), end-stage renal disease (6%), congestive heart failure (5%), collagen vascular disease (5%), and tuberculosis or bacterial infection (4%). Pericardial effusions often result from primary cardiac disease, occurring in 14% of patients with congestive heart failure, 21% of patients with valvular heart disease, and 15% of patients with myocardial infarction.²⁰ Effusions are extremely common after cardiac surgery,²¹ although large effusions causing tamponade are rare in this setting.²²

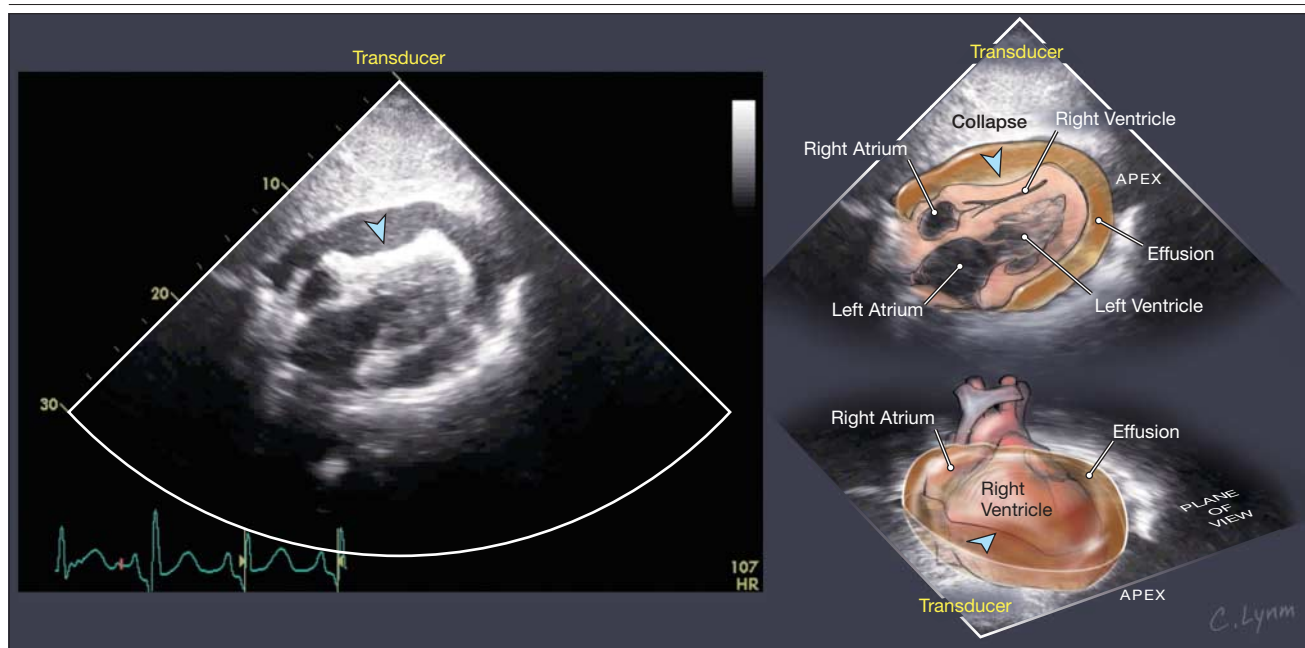
When and How to Perform the Clinical Examination for Cardiac Tamponade

In the nonurgent setting, cardiac tamponade is not typically a consideration unless the patient has an underlying cause with relevant symptoms or suggestive signs. Thus, the astute clinical epidemiologist will infer correctly that cardiac tamponade has been studied mostly in selected patients at risk of having the condition on the basis of symptoms and signs. In fact, the recent literature has focused almost entirely on patients with known pericardial effusion on echocardiography. These studies will have a tendency to overestimate the sensitivity of symptoms and signs in unselected patients.

Symptoms

The important symptoms include dyspnea, chest pain, or fullness.^{15,23} Patients may report nausea or abdominal pain from hepatic and visceral congestion or dysphagia from esophageal compression.^{15,23} Nonspecific symptoms such as lethargy, fever,

Figure 2. Echocardiogram of a 62-Year-Old Woman With Advanced Lung Cancer and Malignant Pericardial Effusion Causing Cardiac Tamponade



In this subcostal view captured in early ventricular diastole, a large, circumferential pericardial effusion measuring 3.3 cm in maximal diameter is compressing the heart, and the right ventricle is completely collapsed (see video at <http://jama.com/cgi/content/full/297/16/1810/DC1>).

cough, weakness, fatigue, anorexia, and palpitations also occur.²³ Because patients with acute cardiac tamponade are critically ill and often in shock, the clinical history may not be obtainable.

Signs

The physical examination begins with an assessment of vital signs and, depending on the degree of hemodynamic compromise, may reveal tachycardia, hypotension, and tachypnea. The classic findings of tamponade were described in 1935 by thoracic surgeon Claude Schaeffer Beck.²⁴ The Beck triad is characterized by decreasing arterial blood pressure, increasing jugular venous pressure, and a small, quiet heart. This triad was seen in surgical patients with acute tamponade from intrapericardial hemorrhage due to trauma or to myocardial or aortic rupture. This “surgical tamponade” is distinct from that seen in medical patients, who generally develop pericardial effusions slowly, and in whom the findings of the Beck triad may not be present at all.²⁵ Some medical patients, especially those with preexisting hypertension, may actually be hypertensive with tamponade physiology.²⁶ A fever associated with a pericardial effusion suggests an infectious etiology but also could be associated with immune-mediated connective tissue disease such as systemic lupus erythematosus.

Pulsus Paradoxus

The examiner should evaluate the patient for the presence of pulsus paradoxus, a phenomenon originally described by Adolf Kussmaul in 1873 as a palpable diminution of the radial pulse on inspiration in patients with cardiac tamponade.²⁷ Pulsus paradoxus is not a paradox at all, but an exaggeration of the normal inspiratory decrease in blood pressure.²⁸ This decrease occurs because negative intrapleural pressures during inspiration cause increased venous return and filling of the right heart, which result in bowing of the septum to the left, decreasing filling of the left heart. In the normal heart, the consequence of this phenomenon, known as ventricu-

lar interdependence, is a mildly decreased stroke volume and blood pressure during inspiration. Opposite changes occur during expiration. In cardiac tamponade, ventricular interdependence is exaggerated because high pericardial pressure compresses the entire heart; during inspiration, left heart filling is more dramatically restricted by right heart filling.²⁹

Pulsus paradoxus can be detected by palpating the radial pulse and noting an inspiratory diminution of the pulse during normal respirations. It is most commonly measured using a manual sphygmomanometer (FIGURE 3). During normal respirations, the examiner slowly deflates the sphygmomanometer cuff while listening for the first Korotkoff sounds. These sounds are initially intermittent and respirophasic, becoming audible with expiration and inaudible with inspiration. With further cuff deflation, the Korotkoff sounds become audible throughout the respiratory cycle. The clinician records the systolic pressure at which Korotkoff sounds are first audible and the systolic pressure at which they are audible constantly through a respiratory cycle. The presence of a pulsus paradoxus may also be detected by observing the inspiratory diminution of the peripheral pulse on an arterial catheter tracing or pulse oximeter (Figure 3).^{30,31}

Most textbooks define a greater than 10-mm Hg difference between the initial detection of sounds on expiration and the constant presence of sounds with each heartbeat through the respiratory cycle as a “pulsus paradoxus.”³² Some experts suggest that the absolute value of pulsus paradoxus should be interpreted as a percentage of the pulse pressure or as a percentage of the expiratory systolic pressure.^{15,33,34} “Total paradox,” also known as “pulse obliteration,” is defined as inspiratory disappearance of the brachial and radial pulses, with total disappearance of the Korotkoff sounds.²⁵

Many conditions may mask the presence of pulsus paradoxus, including hypotension, pericardial adhesions, aortic regurgitation, atrial septal defects,

and right ventricular hypertrophy.²³ Likewise, other conditions can create a pulsus paradoxus, including severe obstructive pulmonary disease, congestive heart failure, mitral stenosis, massive pulmonary embolism, severe hypovolemic shock, obesity, and tense ascites.^{13,23}

Other Signs

Patients with cardiac tamponade often have an elevated jugular venous pressure at bedside examination, but the sensitivity of this finding may be reduced by the patient’s body habitus and, theoretically, in the setting of hypovolemia. The Kussmaul sign, an inspiratory elevation of the jugular venous pressure, should not be seen unless underlying constrictive disease exists.^{13,15}

On cardiac auscultation, the examiner may note diminished heart sounds, although this finding may also be observed in patients with large chests or chronic obstructive pulmonary disease. Although pericardial friction rubs are often believed to occur only in patients with pericarditis and relatively small effusions, some patients with tamponade have a pericardial rub.^{8,25,35} One study demonstrated that a rub may be present with very large effusions, so the presence of a rub is not a useful clue to the size of the effusion.³⁶

Electrocardiogram and Chest Radiograph

The electrocardiogram and chest radiograph support the diagnosis of a large pericardial effusion causing tamponade. Findings on an electrocardiogram indicating a large pericardial effusion include low QRS voltage, electrical alternans (changes in the amplitude or morphology of the P, QRS, and ST-T waves from one beat to the next, resulting from cardiac oscillation within the pericardial fluid³⁷), atrial arrhythmias, and, if pericardial inflammation is present, ST-segment elevation and PR-segment depression. Depending on the size of the effusion, the chest radiograph may be normal or may demonstrate an enlarged, globular cardiac silhouette and/or an epicardial fat stripe or “double lucency” sign on lateral views.³⁸

METHODS
Literature Search and Data Collection

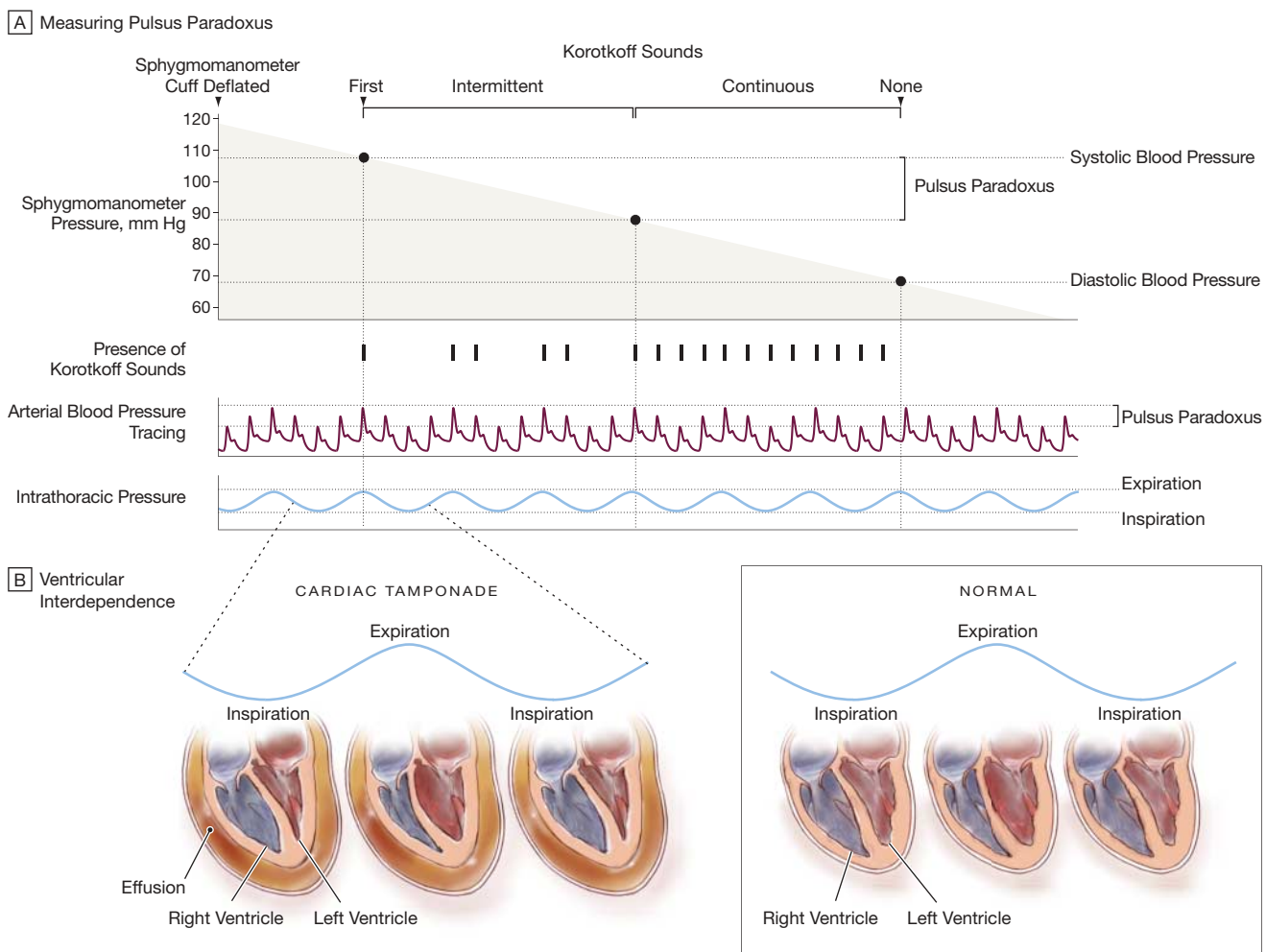
We performed a structured MEDLINE search (January 1, 1966, to December 31, 2006) to identify English-language articles pertinent to the clinical examination of patients with cardiac tamponade. Keywords used included *physical examination, medical history taking, predictive value, decision support techniques,*

Bayes theorem, cardiac auscultation, professional competence, sensitivity and specificity, reproducibility of results, observer variation, diagnostic tests, routine, electrocardiography, pericardium, pericardial disease, pericarditis, pericardial effusion, pericardial tamponade, tamponade, and cardiac tamponade. Two authors (C.L.R., M.A.M.) independently reviewed the abstracts of the search and retrieved potentially relevant articles. To identify

additional articles, we reviewed the reference lists of articles that were retrieved and references cited in cardiology and physical diagnosis textbooks.^{32,39-41}

We included articles reporting the results of original studies that evaluated the history, physical examination, and routine diagnostic tests such as electrocardiography or plain chest radiography compared with a reference standard for the diagnosis of cardiac

Figure 3. Measurement and Mechanism of Pulsus Paradoxus



A, The examiner inflates the sphygmomanometer cuff fully, listens for Korotkoff sounds as the cuff is slowly deflated, and then notes the pressure at which Korotkoff sounds are initially audible only during expiration. As the cuff is further deflated, the examiner notes the pressure at which Korotkoff sounds become audible during expiration and inspiration. The difference between these 2 pressures is the pulsus paradoxus. In cardiac tamponade, the pulsus paradoxus measures greater than 10 mm Hg. Inspiratory diminution in the pulse wave amplitude seen on this arterial tracing demonstrates pulsus paradoxus. A similar phenomenon may be observed on a pulse oximeter waveform. B, During inspiration in the normal heart, negative intrapleural pressures increase venous return to the right ventricle and decrease pulmonary venous return to the left ventricle by increasing pulmonary reservoir for blood. As a result of increased right ventricular distention, the interventricular septum bows slightly to the left, and the distensibility, filling, and stroke volume of the left ventricle are mildly reduced. In expiration, these changes are reciprocal, resulting in the septum bowing to the right and a mild reduction in right ventricular filling. In the presence of cardiac tamponade, the reciprocal changes seen in the normal heart are exaggerated when the pericardial sac is filled with fluid, thus limiting distensibility of the entire heart. This results in a more dramatic reduction in filling of the left ventricle during inspiration, exacerbating the normal inspiratory decrease in stroke volume and blood pressure.

tamponade. Acceptable reference standards included pericardiocentesis with right heart catheterization and echocardiography. We excluded studies dealing with pericardial diseases other than cardiac tamponade, as well as studies of patients with cardiac tamponade after cardiac surgery. We also excluded those with fewer than 15 patients; similar exclusions of small studies have been used in prior reviews in The Rational Clinical Examination series.^{42,43}

Articles were graded for methodological quality.⁴⁴ Level 1 studies independently compare a symptom or sign with an acceptable reference standard of diagnosis among a large number of consecutive patients. Level 2 studies meet the criteria for level 1 studies but have fewer patients. Level 3 studies examine nonconsecutive patients suspected of having the target disorder, but, as in level 1 and 2 studies, the patients are identified independently of the reference standard and the results of the reference standard are interpreted blinded to the signs and symptoms. Level 4 studies are non-independent comparisons of signs and symptoms vs a gold standard among patients with, and perhaps without, the target condition. Level 4 studies may therefore include implicit retrospective reviews of small groups and case series literature.

Data Analysis

When 3 or more studies presented data on a particular finding, we calculated pooled sensitivities and confidence intervals (CIs) using a random effects model; otherwise, we report the point estimate or range. The data were analyzed using R version 2.2.0.⁴⁵

RESULTS

Study Characteristics

Of the 787 studies identified using our search strategy, 8 that included a total of 300 patients met our inclusion criteria (TABLE 1). All studies were of level 4 quality. No studies assessed the precision of the clinical examination in cardiac tamponade.

Six of the 8 studies used right heart catheterization and pericardiocentesis as

the reference standard for the diagnosis of cardiac tamponade. Guberman et al²⁵ included patients with clinical findings consistent with tamponade (elevated jugular venous pressure and pulsus paradoxus) and the documentation of pericardial effusion by echocardiography or other means. Gibbs et al⁴⁷ included patients diagnosed with cardiac tamponade using echocardiographic criteria. One study included control patients without pericardial effusion to evaluate the sensitivity and specificity of pulsus paradoxus in diagnosing tamponade.^{9,33}

Accuracy of Symptoms for Cardiac Tamponade

No studies provide data for calculating the likelihood ratios (LRs) of symptoms that suggest cardiac tamponade.

However, 2 studies examining 80 patients report the sensitivities of the clinical history among patients with pericardial effusion referred for pericardiocentesis (TABLE 2).^{6,47} Most patients with cardiac tamponade have dyspnea (sensitivity, 87%-88%). Chest pain, cough, fever, lethargy, and palpitations occur in 25% or less of patients.

Accuracy of the Physical Examination for Cardiac Tamponade

One study adequately evaluated pulsus paradoxus among patients with and without cardiac tamponade (TABLE 3), allowing calculation of LR. Curtiss et al³³ studied 65 patients with known pericardial effusion referred for pericardiocentesis for suspected tamponade and

Table 1. Studies Assessing the Accuracy of the Clinical Examination for Cardiac Tamponade*

Source	No. of Patients	Study Design/ Patient Population	Reference Standard
Reddy et al, ³⁴ 1978	19	Retrospective chart review of patients with pericardial effusion referred for pericardiocentesis	Hemodynamic findings before and after pericardiocentesis
Guberman et al, ²⁵ 1981	56	Retrospective chart review of patients with cardiac tamponade	Clinical criteria including elevated jugular venous pressure, pulsus paradoxus, and documentation of pericardial effusion
Singh et al, ⁹ 1984	16	Prospective cohort of patients with pericardial effusion referred for pericardiocentesis	Hemodynamic findings before and after pericardiocentesis
Curtiss et al, ³³ 1988	65	Prospective cohort of patients with pericardial effusion referred for pericardiocentesis	Hemodynamic findings before and after pericardiocentesis
Levine et al, ⁶ 1991	50	Prospective cohort of patients with suspected cardiac tamponade referred for pericardiocentesis	Hemodynamic findings before and after pericardiocentesis
Brown et al, ²⁶ 1992	18	Prospective cohort of patients with cardiac tamponade referred for pericardiocentesis	Hemodynamic findings before and after pericardiocentesis
Cooper et al, ⁴⁶ 1995	30	Retrospective chart review of patients with pericardial effusion referred for pericardiocentesis	Relief of symptoms of dyspnea by pericardiocentesis
Gibbs et al, ⁴⁷ 2000	46	Retrospective chart review of patients with pericardial effusion referred for pericardiocentesis	Echocardiographic evidence of cardiac tamponade

*All studies were quality level 4.

used a 20% or greater increase in cardiac output after pericardiocentesis as the reference standard for tamponade. Pulsus paradoxus was measured using

Table 2. Sensitivity of the Clinical History in the Diagnosis of Cardiac Tamponade

Sign/ Symptom	Levine et al, ⁶ 1991 (N = 50)	Cooper et al, ⁴⁶ 1995 (N = 30)
Dyspnea	88	87
Fever		25
Chest pain		20
Cough	10	7
Lethargy		3
Palpitations		3

simultaneous recordings of brachial or femoral artery pressure, electrocardiogram, and a thermistor output for respiratory phase identification. The LR for a pulsus paradoxus greater than 12 mm Hg was 5.9 (95% CI, 2.4-14) and for a cutpoint of greater than 10 mm Hg was 3.3 (95% CI, 1.8-6.3).³³ When the pulsus paradoxus was 10 mm Hg or less, cardiac tamponade was unlikely (LR, 0.03; 95% CI, 0.01-0.24) and was similarly unlikely when a higher pulsus paradoxus threshold of 12 mm Hg or less was used (LR, 0.03; 95% CI, 0-0.21).³³

Eight studies of 295 patients reported the sensitivity of various components of the physical examination in cardiac tamponade (TABLE 4). All but 1 of these studies²⁵ were in patients with pericardial effusion referred for pericardiocentesis. The most common findings among patients with cardiac tamponade were tachycardia, elevated jugular venous pressure, and pulsus paradoxus, with pooled sensitivities ranging from 76% to 82%. Hypotension and diminished heart sounds were insensitive (26% and 28%, respectively). Hypertension can occur in patients with tamponade but primarily occurs in patients with preexisting hypertension (sensitivity, 33%; 95% CI, 11%-55%).²⁶ Guberman et al²⁵ noted that tachypnea was a common finding in their study of 56 patients (sensitivity, 80%; 95% CI, 70%-90%).

Table 3. Sensitivity, Specificity, and Positive and Negative Likelihood Ratios (LRs) of Pulsus Paradoxus in the Diagnosis of Cardiac Tamponade*

	Pulsus Paradoxus, mm Hg†	
	>12	>10
Sensitivity, %	98	98
Specificity, %	83	70
LR (95% CI)		
Positive	5.9 (2.4-14)	3.3 (1.8-6.3)
Negative	0.03 (0-0.21)	0.03 (0.01-0.24)

Abbreviation: CI, confidence interval.

*All data from Curtiss et al (N = 65).³³

†Measured using an intra-arterial transducer.

Accuracy of Electrocardiography and Chest Radiography

The electrocardiographic findings of cardiac tamponade lacked sensitivity (TABLE 5). The pooled sensitivity of low QRS voltage was only 42% (95% CI,

Table 4. Sensitivity of the Physical Examination in the Diagnosis of Cardiac Tamponade

Sign	%								
	Reddy et al, ³⁴ 1978 (N = 19)	Guberman et al, ²⁵ 1981 (N = 56)	Singh et al, ³ 1984 (N = 16)	Curtiss et al, ³³ 1988 (N = 65)	Levine et al, ⁶ 1991 (N = 50)	Brown et al, ²⁶ 1992 (N = 18)	Cooper et al, ⁴⁶ 1995 (N = 25)*	Gibbs et al, ⁴⁷ 2000 (N = 46)	Pooled Sensitivity (95% CI)
Pulsus paradoxus >10 mm Hg	71††	77§	75§	98‡	86		56	80	82 (72-92)
Tachycardia		77			74		65	87	77 (69-85)
Hypotension		35			14		30	24	26 (16-36)
Hypertension ¶						33			
Tachypnea		80							
Diminished heart sounds		34			24			24	28 (21-35)
Elevated JVP			88		74		53	87	76 (62-90)
Peripheral edema		21			28				
Pericardial rub		29	19						
Hepatomegaly		55			28				
Kussmaul sign							26		
Pulse pressure, mm Hg									
>0		54							
>100		12							
Total paradox		23							

Abbreviations: CI, confidence interval; JVP, jugular venous pressure.

*Not all patients had documentation of clinical findings.

†Defined pulsus paradoxus as expiratory systolic pressure-inspiratory systolic pressure/expiratory systolic pressure >10%.

‡Pulsus paradoxus measured with intra-arterial transducer.

§Pulsus paradoxus measured with sphygmomanometer or intra-arterial transducer.

||Pulsus paradoxus measured with sphygmomanometer.

¶Systolic blood pressure >140 mm Hg.

Table 5. Sensitivity of the Electrocardiogram in the Diagnosis of Cardiac Tamponade

	%						
	Reddy et al, ³⁴ 1978 (N = 19)	Guberman et al, ²⁵ 1981 (N = 53)*	Singh et al, ⁸ 1984 (N = 16)	Levine et al, ⁶ 1991 (N = 50)	Cooper et al, ⁴⁶ 1995 (N = 23)	Gibbs et al, ⁴⁷ 2000 (N = 46)*	Pooled Sensitivity (95% CI)
Low voltage		40	50	56	22	39	42 (32-53)
Atrial arrhythmia	0	9		4			6 (1-11)
Electrical alternans		21		16			
ST-segment elevation		30	18				
PR-segment depression				18			

Abbreviation: CI, confidence interval.

*Not all patients had documentation of clinical findings.

32%-53%), and 2 studies reported that electrical alternans had a sensitivity of only 16% to 21%. Atrial arrhythmias are infrequent in cardiac tamponade, as are findings associated with acute pericarditis (PR-segment depression and ST-segment elevation).

Cardiomegaly on chest radiography is fairly useful in the diagnosis of cardiac tamponade, with a pooled sensitivity of 89% (95% CI, 73%-100%) in the 4 studies of 165 patients that evaluated this finding (TABLE 6).

SCENARIO RESOLUTIONS

Case 1

The patient has several important negative findings, notably an absence of a pulsus paradoxus, a jugular venous pressure that is not elevated, and no enlargement of the cardiac silhouette on chest radiograph. Knowing that these are relatively sensitive findings, you are reassured that despite her known effusion, cardiac tamponade is unlikely, and you entertain other possibilities to account for her symptoms.

Case 2

The patient has a pulsus paradoxus in the setting of a known pericardial effusion, and although the echocardiogram is nondiagnostic and the rest of his examination is normal, this clinical finding alone increases the likelihood of tamponade physiology. You arrange for urgent pericardiocentesis, which demonstrates elevated intrapericardial pressures and equalization with intracardiac pressures. Drainage of the effusion leads to resolution of the elevated pulsus paradoxus and improvement in symptoms.

Table 6. Sensitivity of the Chest Radiograph in the Diagnosis of Cardiac Tamponade

Source	Patients, No.	Cardiomegaly, %
Guberman et al, ²⁵ 1981	53	95
Singh et al, ⁸ 1984	16	94
Levine et al, ⁶ 1991	50	68
Gibbs et al, ⁴⁷ 2000	46	100
Pooled sensitivity (95% CI)		89 (73-100)

Abbreviation: CI, confidence interval.

CONCLUSIONS

Based on our review of the literature, dyspnea, tachycardia, elevated jugular venous pressure, pulsus paradoxus, or cardiomegaly on chest radiograph is seen in 70% or more of patients with a known pericardial effusion and cardiac tamponade. However, 50% or less of patients will have diminished heart sounds, hypotension, or low voltage on electrocardiogram. Based on 1 study, the presence of a pulsus paradoxus greater than 10 mm Hg increases the likelihood of cardiac tamponade, while a pulsus paradoxus of 10 mm Hg or less decreases the likelihood. The presence and degree of pulsus paradoxus may be helpful to predict the degree of hemodynamic compromise in tamponade in patients with an effusion who are suspected of having this condition. In general there is a paucity of evidence supporting the diagnostic accuracy of the clinical examination for cardiac tamponade, and it must be stressed that all studies enrolled patients with a previously established pericardial effusion. We found no studies that evaluated interrater reliability of clinical findings or that included patients not already known or highly suspected to have

cardiac tamponade. As a result, we are unable to comment on whether the clinical examination is useful in other scenarios (eg, to exclude tamponade in patients who have not yet had an echocardiogram). In addition, the studies reviewed all took place in academic medical centers, raising concerns of referral bias and questions about generalizability to the community setting. The available evidence is also limited in that no studies have analyzed the predictive value of a combination of multiple findings. Finally, cardiac tamponade is a continuum of hemodynamic effects and the patients included in published studies are likely heterogeneous as to their position on that continuum, so the sensitivities and specificities of findings on clinical examination will vary depending on the severity of patients studied.

Two reviewed studies explicitly used invasive monitoring (ie, intra-arterial transducers), rather than a sphygmomanometer, to measure pulsus paradoxus.^{33,34} While one would expect that invasive measurement would be more accurate than manual measurement, the literature lacks studies directly comparing the accuracy of these methods. Nonetheless, we

found the sensitivity of pulsus paradoxus was similar in studies using different measurement techniques.^{6,8}

In summary, when faced with a patient with a known pericardial effusion, the clinical examination may help guide decisions about the appropriateness of expectant management or more urgent, invasive intervention.

Author Contributions: Dr Choudry had full access to all of the data in the study and takes responsibility for the integrity of the data and the accuracy of the data analysis.

Study concept and design: Roy, Choudhry.

Acquisition of data: Roy, Minor, Choudhry.

Analysis and interpretation of data: Roy, Brookhart, Choudhry.

Drafting of the manuscript: Roy, Choudhry.

Critical revision of the manuscript for important intellectual content: Roy, Minor, Brookhart, Choudhry.

Statistical analysis: Brookhart, Choudhry.

Administrative, technical, or material support: Roy, Minor, Choudhry.

Study supervision: Choudhry.

Financial Disclosures: None reported.

Acknowledgment: We thank Robert L. Trowbridge, MD (Maine Hospitalist Service, Maine Medical Center, Portland), and David H. Newman, MD (Department of Emergency Medicine, St Luke's/Roosevelt Hospital Center, New York, NY), for their helpful comments on an earlier version of this article. Drs Trowbridge and Newman received no compensation for their contributions.

REFERENCES

- Reddy PS, Curtiss EI, Uretsky BF. Spectrum of hemodynamic changes in cardiac tamponade. *Am J Cardiol.* 1990;66:1487-1491.
- Appleton CP, Hatle LK, Popp RL. Cardiac tamponade and pericardial effusion: respiratory variation in transvalvular flow velocities studied by Doppler echocardiography. *J Am Coll Cardiol.* 1988;11:1020-1030.
- Fowler NO. The significance of echocardiographic-Doppler studies in cardiac tamponade. *J Am Coll Cardiol.* 1988;11:1031-1033.
- Shaver JA, Reddy PS, Curtiss EI, Ziady GM, Reddy SC. Noninvasive/invasive correlates of exaggerated ventricular interdependence in cardiac tamponade. *J Cardiol.* 2001;37(suppl 1):71-76.
- Engel PJ. Echocardiography in pericardial disease. *Cardiovasc Clin.* 1983;13:181-200.
- Levine MJ, Lorell BH, Diver DJ, Come PC. Implications of echocardiographically assisted diagnosis of pericardial tamponade in contemporary medical patients: detection before hemodynamic embarrassment. *J Am Coll Cardiol.* 1991;17:59-65.
- Mercé J, Sagrista-Sauleda J, Permanyer-Miralda G, Evangelista A, Soler-Soler J. Correlation between clinical and Doppler echocardiographic findings in patients with moderate and large pericardial effusion: implications for the diagnosis of cardiac tamponade. *Am Heart J.* 1999;138:759-764.
- Singh S, Wann LS, Schuchard GH, et al. Right ventricular and right atrial collapse in patients with cardiac tamponade—a combined echocardiographic and hemodynamic study. *Circulation.* 1984;70:966-971.
- Singh S, Wann LS, Klopfenstein HS, Hartz A, Brooks HL. Usefulness of right ventricular diastolic collapse in diagnosing cardiac tamponade and comparison to pulsus paradoxus. *Am J Cardiol.* 1986;57:652-656.
- Engel PJ, Hon H, Fowler NO, Plummer S. Echocardiographic study of right ventricular wall motion in cardiac tamponade. *Am J Cardiol.* 1982;50:1018-1021.
- Klopfenstein HS, Schuchard GH, Wann LS, et al. The relative merits of pulsus paradoxus and right ventricular diastolic collapse in the early detection of cardiac tamponade: an experimental echocardiographic study. *Circulation.* 1985;71:829-833.
- Fowler NO. Cardiac tamponade: a clinical or an echocardiographic diagnosis? *Circulation.* 1993;87:1738-1741.
- Spodick DH. Pericarditis, pericardial effusion, cardiac tamponade, and constriction. *Crit Care Clin.* 1989;5:455-476.
- Fowler NO. Physiology of cardiac tamponade and pulsus paradoxus, II: physiological, circulatory, and pharmacological responses in cardiac tamponade. *Mod Concepts Cardiovasc Dis.* 1978;47:115-118.
- Hancock EW. Cardiac tamponade. *Med Clin North Am.* 1979;63:223-237.
- Reddy PS, Curtiss EI. Cardiac tamponade. *Cardiol Clin.* 1990;8:627-637.
- Levy PY, Corey R, Berger P, et al. Etiologic diagnosis of 204 pericardial effusions. *Medicine (Baltimore).* 2003;82:385-391.
- Sagrìsta-Sauleda J, Merce J, Permanyer-Miralda G, Soler-Soler J. Clinical clues to the causes of large pericardial effusions. *Am J Med.* 2000;109:95-101.
- Atar S, Chiu J, Forrester JS, Siegel RJ. Bloody pericardial effusion in patients with cardiac tamponade: is the cause cancerous, tuberculous, or iatrogenic in the 1990s? *Chest.* 1999;116:1564-1569.
- Maisch B. Pericardial diseases, with a focus on etiology, pathogenesis, pathophysiology, new diagnostic imaging methods, and treatment. *Curr Opin Cardiol.* 1994;9:379-388.
- Weitzman LB, Tinker WP, Kronzon I, Cohen ML, Glassman E, Spencer FC. The incidence and natural history of pericardial effusion after cardiac surgery—an echocardiographic study. *Circulation.* 1984;69:506-511.
- Kuvin JT, Harati NA, Pandian NG, Bojar RM, Khabbaz KR. Postoperative cardiac tamponade in the modern surgical era. *Ann Thorac Surg.* 2002;74:1148-1153.
- Spodick DH. Acute cardiac tamponade. *N Engl J Med.* 2003;349:684-690.
- Beck C. Two cardiac compression triads. *J Am Med Assoc.* 1935;104:714-716.
- Guberman BA, Fowler NO, Engel PJ, Gueron M, Allen JM. Cardiac tamponade in medical patients. *Circulation.* 1981;64:633-640.
- Brown J, MacKinnon D, King A, Vanderbush E. Elevated arterial blood pressure in cardiac tamponade. *N Engl J Med.* 1992;327:463-466.
- Kussmaul A. Über schwierige Mediastino-Perikarditis und den paradoxen Puls. *Berl Klin Wochenschr.* 1873;10:433-435.
- Swami A, Spodick DH. Pulsus paradoxus in cardiac tamponade: a pathophysiologic continuum. *Clin Cardiol.* 2003;26:215-217.
- Fowler NO. Physiology of cardiac tamponade and pulsus paradoxus, I: mechanisms of pulsus paradoxus in cardiac tamponade. *Mod Concepts Cardiovasc Dis.* 1978;47:109-113.
- Hartert TV, Wheeler AP, Sheller JR. Use of pulse oximetry to recognize severity of airflow obstruction in obstructive airway disease: correlation with pulsus paradoxus. *Chest.* 1999;115:475-481.
- Frey B, Butt W. Pulse oximetry for assessment of pulsus paradoxus: a clinical study in children. *Intensive Care Med.* 1998;24:242-246.
- Orient JM, Sapira JD. *Sapira's Art & Science of Bedside Diagnosis.* 3rd ed. Philadelphia, Pa: Lippincott Williams & Wilkins; 2005.
- Curtiss EI, Reddy PS, Uretsky BF, Cecchetti AA. Pulsus paradoxus: definition and relation to the severity of cardiac tamponade. *Am Heart J.* 1988;115:391-398.
- Reddy PS, Curtiss EI, O'Toole JD, Shaver JA. Cardiac tamponade: hemodynamic observations in man. *Circulation.* 1978;58:265-272.
- Spodick DH. Pericardial rub: prospective, multiple observer investigation of pericardial friction in 100 patients. *Am J Cardiol.* 1975;35:357-362.
- Markiewicz W, Brik A, Brook G, Edoute Y, Monakier I, Markiewicz Y. Pericardial rub in pericardial effusion: lack of correlation with amount of fluid. *Chest.* 1980;77:643-646.
- Goldberger AL, Shabetai R, Bhargava V, West BJ, Mandell AJ. Nonlinear dynamics, electrical alternans, and pericardial tamponade. *Am Heart J.* 1984;107:1297-1299.
- Heinsimer JA, Collins GJ, Burkman MH, Roberts L Jr, Chen JT. Supine cross-table lateral chest roentgenogram for the detection of pericardial effusion. *JAMA.* 1987;257:3266-3268.
- Zipes DP, Braunwald E. *Braunwald's Heart Disease: A Textbook of Cardiovascular Medicine.* 7th ed. Philadelphia, Pa: WB Saunders; 2005.
- Bates B, Bickley LS, Hoekelman RA. *A Guide to Physical Examination and History Taking.* 6th ed. Philadelphia, Pa: Lippincott; 1995.
- Fuster V, Hurst JW. *Hurst's the Heart.* 11th ed. New York, NY: McGraw-Hill; 2004.
- Choudhry NK, Etchells EE. Does this patient have aortic regurgitation? *JAMA.* 1999;281:2231-2238.
- Klompas M. Does this patient have an acute thoracic aortic dissection? *JAMA.* 2002;287:2262-2272.
- Holleman DR Jr, Simel DL. Does the clinical examination predict airflow limitation? [published correction appears in *JAMA.* 1995;273:1334]. *JAMA.* 1995;273:313-319.
- R: *A Language and Environment for Statistical Computing* [computer program]. Version 2.2.0. Vienna, Austria: R Foundation for Statistical Computing; 2003.
- Cooper JP, Oliver RM, Currie P, Walker JM, Swanton RH. How do the clinical findings in patients with pericardial effusions influence the success of aspiration? *Br Heart J.* 1995;73:351-354.
- Gibbs CR, Watson RD, Singh SP, Lip GY. Management of pericardial effusion by drainage: a survey of 10 years' experience in a city centre general hospital serving a multiracial population. *Postgrad Med J.* 2000;76:809-813.